

Oral Janus Kinase Inhibitors May Have A Beneficial Role In The Treatment Of Keloidal Scars: A Case Report

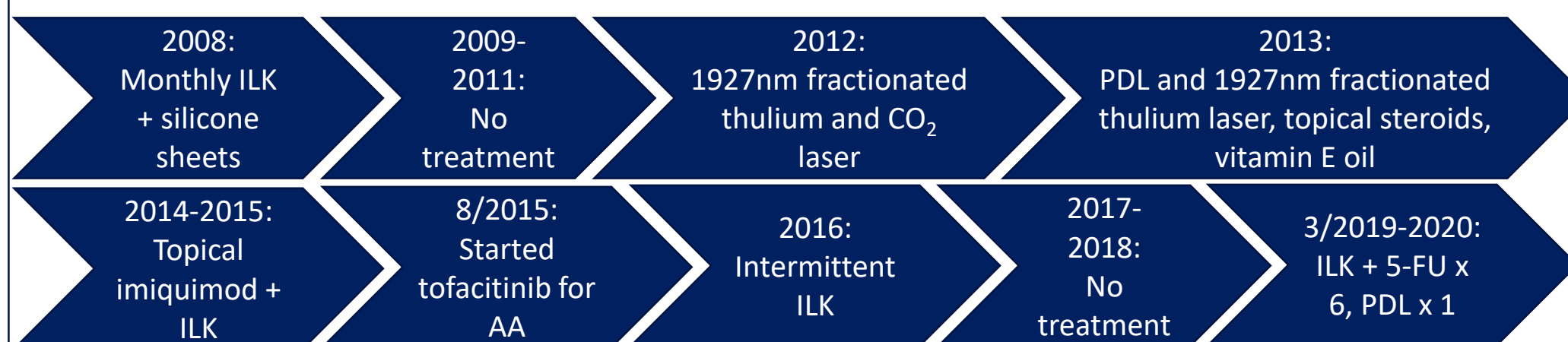
Tiana Kazemi, MD¹; Ronda Farah, MD¹; Maria Hordinsky, MD¹
¹University of Minnesota, Department of Dermatology

Background

- Keloids are often associated with impaired quality of life due to aesthetic considerations and physical discomfort, especially pruritus and pain.^{1,2}
- Unfortunately, successful treatment is challenging due to therapy resistance and recurrence. There is no gold standard of clinical care and a dearth of quality evidence-based treatment guidelines.^{1,2,3}
- The traditional therapeutic treatment ladder includes a stepwise approach from conservative to more invasive treatment options including silicone sheets and topical steroids, intralesional steroids sometimes in combination with 5-fluorouracil, and finally, laser therapy (pulsed dye (PDL), fractional) or surgery (cryosurgery, excision). Alternative therapies include topical imiquimod, intralesional bleomycin and mitomycin, and radiotherapy.^{4,5}
- As keloid pathophysiology is better understood, novel therapies for prevention and treatment are emerging with encouraging results.⁶

Report of a Case

- A 28-year-old female presented to our clinic for evaluation of a symptomatic keloid on the chest due to acne scar excision 12 years prior (Figure 1). Past medical history was also notable for severe alopecia areata (AA), for which she had been started on an oral JAK inhibitor, tofacitinib, 5 years ago with excellent response.
- The patient had undergone a multitude of therapeutic trials for her pruritic keloid as summarized below:



ILK: intralesional kenalog, 5-FU: 5-fluorouracil (intralesional)

- Interestingly, our patient experienced landmark changes with significant decrease in erythema and thinning of her keloid during two periods: 1) after initiation of tofacitinib in 8/2015 (Figure 2), and 2) after serial ILK with 5-FU in 3/2019 (Figure 3). Of note, while she had intermittent ILK throughout the entire treatment course, ILK alone never resulted in appreciable improvement.

Discussion

- Keloids are benign dermal fibroproliferative tumors due to aberrant wound healing with exuberant dermal fibroblast activity resulting in excess deposition of collagen and other extracellular matrix components beyond the site of initial injury.^{3,7-9}
- The pathophysiology of keloid formation is incompletely understood. Cytokines, growth factors, and their receptors are thought to play an important role.^{3,7-9}
- Janus kinases (JAKs) are intracellular tyrosine kinases that activate Signal Transducer and Activator of Transcription (STAT), leading to downstream regulation of gene expression. The JAK/STAT pathway mediates numerous cellular functions and has been implicated in the pathogenesis of many diseases.^{3,7-9}
- Recently, keloid fibroblasts have been shown to have increased receptor tyrosine kinase expression in comparison to fibroblasts in normal skin. Elevated JAK/STAT3 activity promotes tumorigenesis via induction of keloidal fibroblast proliferation and migration. Inhibition *in vitro* results in decreased cell proliferation, fibroblast migration, and collagen production.^{3,7-9}
- Tofacitinib is an oral tyrosine kinase inhibitor that targets the JAK 1, 2, and 3 receptors and is FDA approved for the treatment of rheumatoid arthritis, psoriatic arthritis, and ulcerative colitis.¹⁰ It is often used in Dermatology as an off-label treatment for refractory alopecia with promising results.¹¹
- In our patient, tofacitinib appears to have had a beneficial effect on a pre-existing keloid, likely due to suppression of the JAK/STAT3 pathway as discussed. To our knowledge, this is the first reported case of improvement in a keloid associated with oral JAK inhibitor use. While the cumulative effects of other treatments (especially ILK and 5-FU), cannot be disregarded, nonetheless, the continued improvement during a 2-year treatment hiatus and reports of the role of JAK/STAT3 in keloid pathophysiology offer an exciting insight into a potential new treatment.

Conclusions

- Given emerging understanding of the role of tyrosine kinases in the pathogenesis of keloids, JAK inhibitors such as tofacitinib may represent a novel treatment option. We urge providers prescribing JAK inhibitors to consider monitoring patients for any changes in incidental keloids.

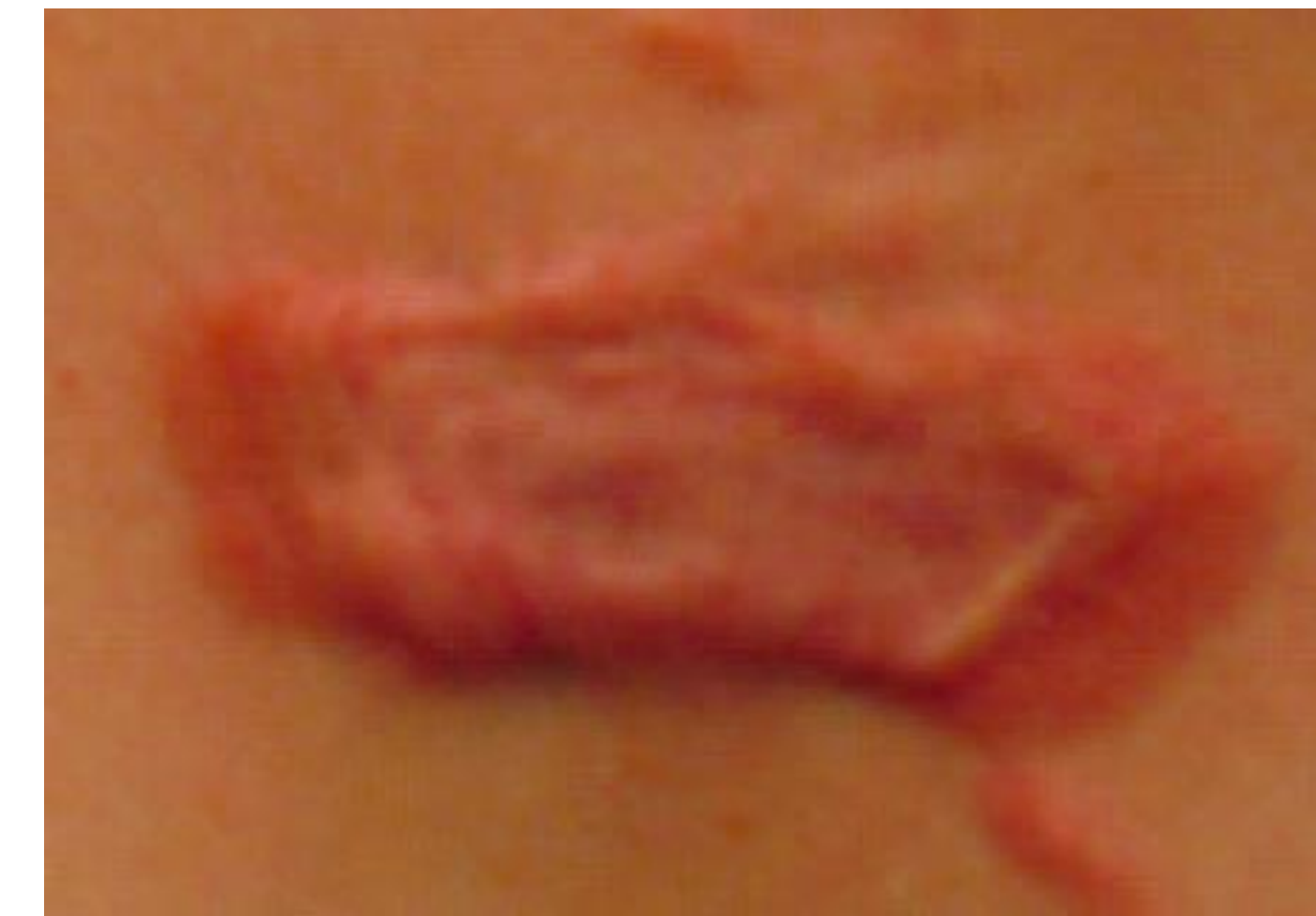

Figure 1. 7/2015, prior to initiating tofacitinib therapy for AA.

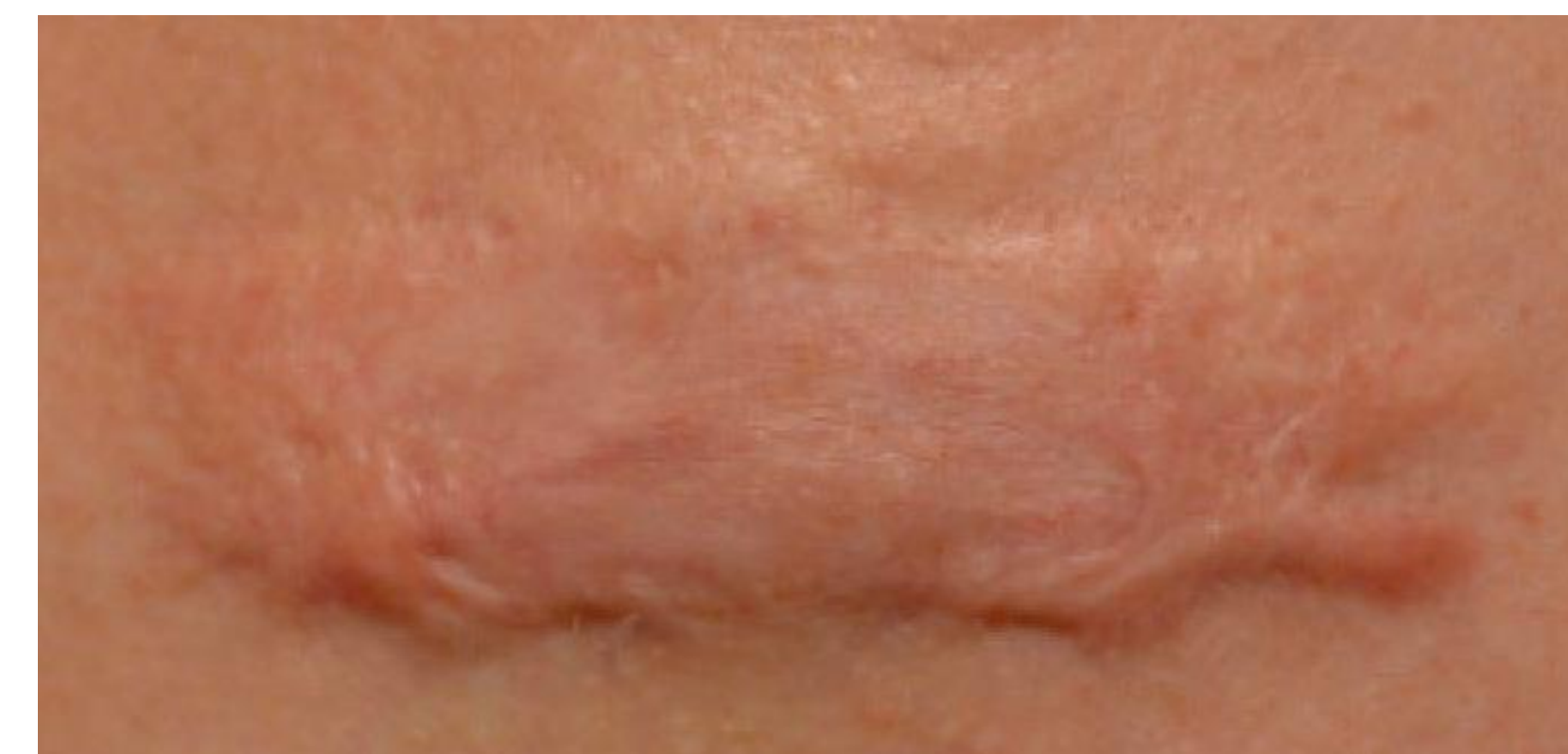

Figure 2. 7/2018, after almost 3 years of tofacitinib therapy with only intermittent ILK to keloid.

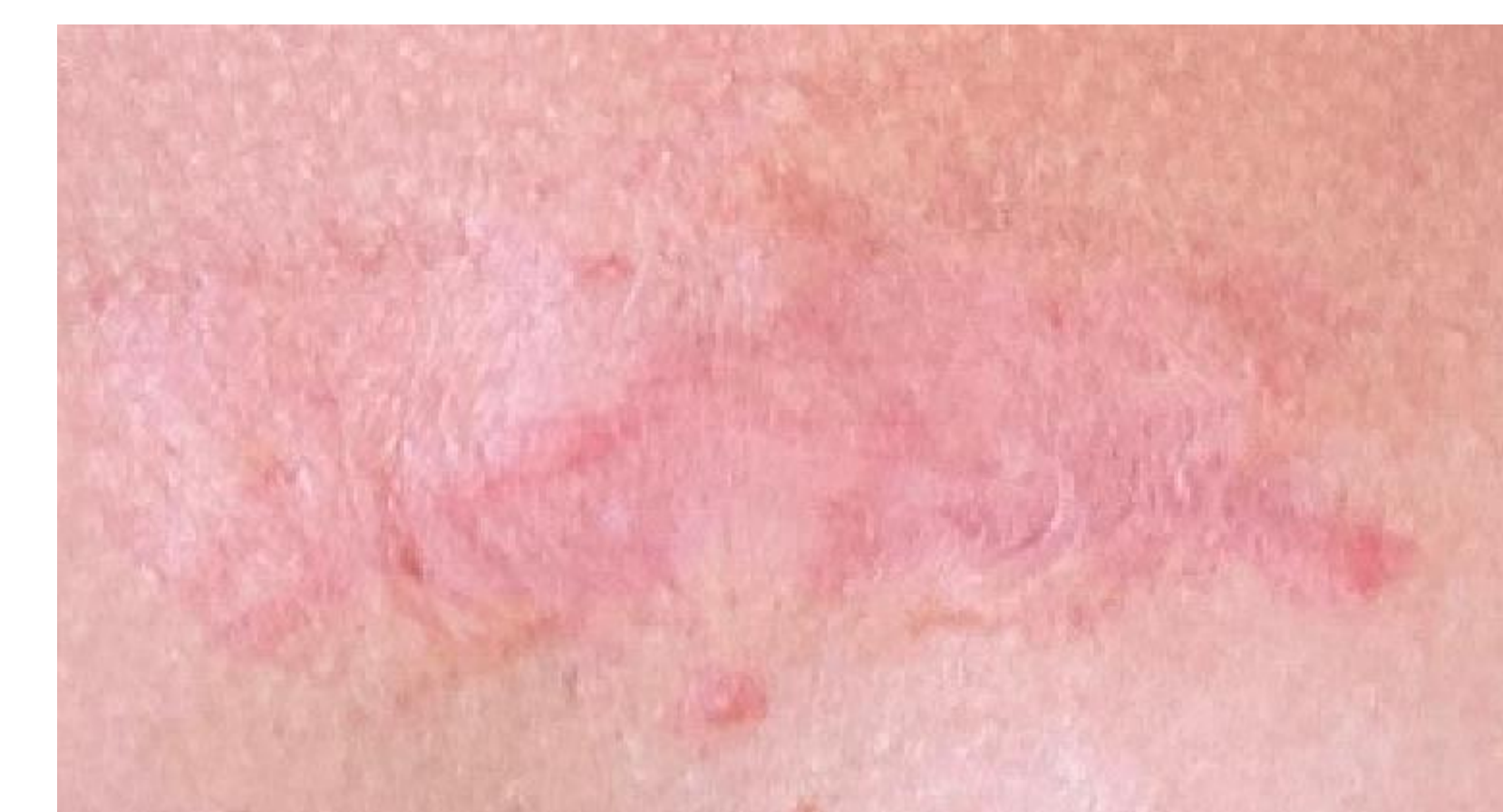

Figure 3. 6/2020, after serial treatments with ILK + 5-FU x 6 and PDL x 1.

Intermittent ILK throughout treatment course

Tofacitinib therapy started

Serial ILK + 5-FU and PDL

Contact

Tiana Kazemi, MD
University of Minnesota, Department of Dermatology
Email: kazem030@umn.edu

References

1. Bijlard E, Kouwenberg CA, Timman R, Hovius SE, Busschbach JJ, Mureau MA. Burden of Keloid Disease: A Cross-sectional Health-related Quality of Life Assessment. *Acta Derm Venereol.* 2017;97(2):225-229.
2. Kouwenberg CA, Bijlard E, Timman R, et al. Emotional quality of life is severely affected by keloid disease: pain and itch are the main determinants of burden. *Plast Reconstr Surg.* 2015;136(4):150-151.
3. Lim CP, Phian TT, Lim U, Cao X. Stat3 contributes to keloid pathogenesis via promoting collagen production, cell proliferation and migration. *Oncogene.* 2006;25(39):5416-25.
4. Gold MH, Maguire M, Mustoe TA, et al. Updated international clinical recommendations on scar management: part 2—algorithms for scar prevention and treatment. *Dermatol Surg.* 2014;40(8):825-31.
5. Berman B, Maderal A, Raphael B. Keloids and Hypertrophic Scars: Pathophysiology, Classification, and Treatment. *Dermatol Surg.* 2017;43 Suppl 1:S3-S18.
6. Betarbet U, Blalock TW. Keloids: A Review of Etiology, Prevention, and Treatment. *J Clin Aesthet Dermatol.* 2020;13(2):33-43.
7. Tan S, Khumalo N, Bayat A. Understanding Keloid Pathobiology From a Quasi-Neoplastic Perspective: Less of a Scar and More of a Chronic Inflammatory Disease With Cancer-Like Tendencies. *Front Immunol.* 2019;10:1810.
8. Gu W, Sun W, Zhang S, Li X, Wei W. Targeted blockade of JAK/STAT3 signaling inhibits proliferation, migration and collagen production as well as inducing the apoptosis of hepatic stellate cells. *Int J Mol Med.* 2016;38(3):903-11.
9. Utito J. IL-6 signaling pathway in keloids: a target for pharmacologic intervention?. *J Invest Dermatol.* 2007;127(1):6-8.
10. Furumoto Y, Gadinai M. The arrival of JAK inhibitors: advancing the treatment of immune and hematologic disorders. *BioDrugs.* 2013;27(5):431-8.
11. Liu LY, Craiglow BG, Dai F, King BA. Tofacitinib for the treatment of severe alopecia areata and variants: A study of 90 patients. *J Am Acad Dermatol.* 2017;76(1):22-28.
12. Torjesen I. An Investigational Drug for Keloids. *Dermatology Times.* <https://www.dermatologytimes.com/view/investigational-drug-keloids>. Published February 7, 2020. Accessed June 20, 2020.